

Cite this article as: Elshafie G, Kumar P, Motamedi-Fakhr S, Iles R, Wilson RC, Naidu B. Measuring changes in chest wall motion after lung resection using structured light plethysmography: a feasibility study. *Interact CardioVasc Thorac Surg* 2016; doi:10.1093/icvts/iwv185.

## Measuring changes in chest wall motion after lung resection using structured light plethysmography: a feasibility study<sup>†</sup>

Ghazi Elshafie<sup>a,b</sup>, Prem Kumar<sup>b</sup>, Shayan Motamedi-Fakhr<sup>c</sup>, Richard Iles<sup>c,d</sup>, Rachel C. Wilson<sup>c</sup> and Babu Naidu<sup>a,b,\*</sup>

<sup>a</sup> Department of Thoracic Surgery, Heart of England NHS Foundation Trust, Birmingham, UK

<sup>b</sup> School of Clinical and Experimental Medicine, The Medical School, University of Birmingham, Birmingham, UK

<sup>c</sup> PneumaCare Ltd, Prospect House, Ely, Cambridgeshire, UK

<sup>d</sup> Evelina London Children's Hospital, London, UK

\* Corresponding author. Department of Thoracic Surgery, Heart of England NHS Foundation Trust, Bordesley Green East, Birmingham B9 5SS, UK. Tel: +44-121-4242000; fax: +44-121-4240562; e-mail: b.naidu@bham.ac.uk (B. Naidu).

Received 30 December 2015; received in revised form 25 April 2016; accepted 29 April 2016

### Abstract

**OBJECTIVES:** We describe the use of structured light plethysmography (SLP)—a novel, non-contact, light-based technique for measuring tidal breathing—among a cohort of patients undergoing lung resection. In this feasibility study, we examined whether changes in chest wall motion or in asynchrony between regions of the thoraco-abdominal wall could be identified after surgery.

**METHODS:** Fifteen patients underwent wedge resection ( $n = 8$ ) or lobectomy ( $n = 7$ ). All patients underwent two SLP assessments (before surgery and on Day 1 post-surgery). Each assessment captured data during 5 min of quiet (tidal) breathing.

**RESULTS:** When data were averaged across all patients, motion on the operated side of the thorax was significantly reduced after surgery (mean change from presurgery  $\pm$  standard deviation:  $-14.7 \pm 16.5\%$ ,  $P = 0.01$ ), while motion on the non-operated side increased ( $15.9 \pm 18.5\%$ ,  $P = 0.01$ ). Thoraco-abdominal asynchrony also increased (mean change  $\pm$  standard deviation:  $43.4 \pm 55.1\%$ ,  $P = 0.01$ ), but no significant difference was observed in right-left hemi-thoracic asynchrony ( $163.7 \pm 230.3\%$ ,  $P = 0.08$ ). When analysed by resection type, lobectomy was associated with reduced and increased motion on the operated and non-operated side, respectively, and with an increase in both right-left hemi-thoracic and thoraco-abdominal asynchrony. No significant changes in motion or asynchrony were identified in patients who underwent wedge resection.

**CONCLUSIONS:** SLP was able to detect changes in chest wall motion and asynchrony after thoracic surgery. Changes in this small group of patients were consistent with the side of the incision and were most apparent in patients undergoing lobectomy.

**Keywords:** Chest wall motion • Lung volume reduction • Structured light plethysmography

### INTRODUCTION

Disruption of the chest wall after thoracic surgery leads to significant patient morbidity [1]. For example, extensive thoracic surgery is associated with a high incidence of pulmonary complications in the postoperative recovery phase [2, 3]. Impairment of respiratory muscle function is an important cause of such postoperative complications [4–8].

Post-surgical measurement of changes in chest wall motion, including asynchronies between thoracic regions, can provide an indication of respiratory muscle function [9, 10]. Quantification of these changes after surgery would enable the impact of different surgical approaches and techniques on chest wall disruption—and

on subsequent recovery—to be assessed. Until recently, there has been no convenient way to measure relative motion between both sides of the chest and between the chest and abdomen immediately after surgery. However, a novel, non-contact, light-based technique that allows measurement of spatial and temporal changes in motion of the whole thoraco-abdominal (TA) wall, and of regions within it, has now been developed. This technique, known as structured light plethysmography (SLP), involves projection of a grid of light onto the patient's chest and abdomen. Changes in the grid pattern caused by the movement of breathing are captured by two digital cameras and then quantified [11]. SLP can measure the displacement of defined regions of the TA wall and can be used to compare changes in absolute motion as well as in asynchrony between regions (e.g. left versus right hemi-thorax or chest versus abdomen).

Here, we describe the use of SLP for the assessment of chest wall motion and asynchrony in a small cohort of patients undergoing lung resection. In this feasibility study, we examined whether any

<sup>†</sup>Abstracts reporting data contained in this manuscript have been presented at the following conferences:

- European Respiratory Society, Munich, September 2014.
- British Thoracic Oncology Group, Dublin, January 2015.
- Society for Cardiothoracic Surgery, Birmingham, March 2016.

consistent changes in motion could be identified after surgery, and conducted preliminary analyses to explore whether changes were associated with the amount of lung removed.

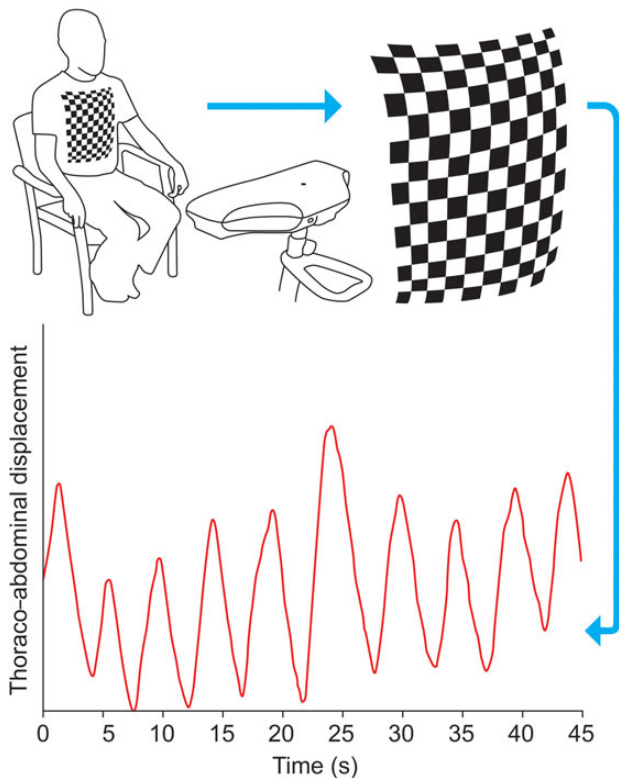
## MATERIALS AND METHODS

Between May 2014 and January 2015, we recruited 15 patients undergoing lung resection at a regional thoracic unit (Department of Thoracic Surgery, Heart of England NHS Foundation Trust, Birmingham, UK). According to clinical need, patients underwent wedge resection ( $n = 8$ ) or lobectomy ( $n = 7$ ).

The study was approved by the UK Health Research Authority National Research Ethics Service (reference number 10/H1202/58) and was performed according to ICH Guidelines for Good Clinical Practice. All patients provided written informed consent.

### Structured light plethysmography measurements

A novel, portable SLP device (Thora-3Di™, PneumaCare Ltd, Cambridgeshire, UK) was used to measure the dynamic motion of different regions of the TA wall. SLP measures both thoracic (chest) and abdominal motion using a grid of light projected onto the TA wall. This grid is 'seen' by a digital vision system, and movement of the grid during tidal breathing is recorded and analysed. Outputs are displayed visually as a 3D-reconstruction of the TA wall, as well as numerically in the form of various tidal breathing parameters [11]. Figure 1 illustrates the working principle of SLP.



**Figure 1:** Structured light plethysmography (SLP) projects a grid of light onto the thoraco-abdominal (TA) wall of a participant. Changes in the grid pattern during quiet (tidal) breathing are recorded using two cameras and the SLP signal is translated into a virtual surface corresponding to the shape of the TA wall of the subject. Average axial displacement of the virtual grid provides a 1D movement-over-time trace from which tidal breathing timing indices can be calculated.

SLP parameters measured during this study were overall chest wall movement, relative contribution, TA asynchrony (TAA) and right-left hemi-thoracic asynchrony (HTA). Overall chest wall movement describes the total displacement of the right and left chest wall during normal breathing. Relative contribution describes how much the displacement of a particular TA region contributes to each tidal breath. Displacement of a selected region of the TA wall (for example, the thorax, abdomen, right hemi-thorax or left hemi-thorax) can be quantified and expressed as a percentage of total displacement or as a percentage of the displacement of another region. Asynchrony (or 'phase') describes the temporal movement of one region with respect to another. When movement in time of one region closely follows that of another region, the two regions are considered to be in synchrony. However, if movement of one region is lagging behind, or is leading, the two regions are said to be asynchronous. Usually, the term 'phase' is used to describe TAA; however, SLP also allows assessment of HTA. Phase is quantified numerically in degrees, where  $0^\circ$  is completely synchronous and  $180^\circ$  is completely asynchronous.

Patients underwent two SLP assessments in the seated position, one before surgery and one at Day 1 postoperatively. Each assessment captured data during 5 min of quiet (tidal) breathing.

### Other clinical measurements

Other measurements included height, weight, Borg breathlessness score, pain score, respiratory rate and presurgery spirometry measurements, including forced expiratory volume in 1 s (FEV1), FEV1 percent of predicted (FEV1%), forced vital capacity (FVC) and FVC percent of predicted (FVC%).

### Statistical analysis

IBM® SPSS® statistics program (Version 22.0.0.0) was used to analyse the data. Changes in relative contribution of the operated side and of the non-operated side as percentages of total motion were calculated pre- to post-surgery for all patients and each defined group. Changes in synchrony (phase) between left and right hemi-thorax (HTA) and between thorax and abdomen (TAA) pre- to post-surgery were also calculated for each group. The percentage change from pre- to post-surgery in the above parameters was then determined. Values are presented as mean  $\pm$  standard deviation unless otherwise stated. The paired Student's *t*-test was used to compare changes in parameters pre- to post-surgery. A two-sample Student's *t*-test was used for between-subgroup comparisons (lobectomy versus wedge). A *P*-value  $<0.05$  represented a statistically significant difference.

## RESULTS

### Patient characteristics

A total of 15 patients were recruited. Baseline patient characteristics are presented in Table 1. Mean age was 67 years and two-thirds of patients were male. None of the 15 patients had a complication following their surgical procedures.

## Changes in chest wall motion pre- to post-surgery (all patients)

Among all patients ( $n = 15$ ), there was a significant reduction in relative contribution of the operated side of the chest on postoperative day 1 compared with preoperative values ( $-14.7 \pm 16.5\%$ ,  $P = 0.01$ ), and a compensatory increase in relative contribution on the non-operated side ( $15.9 \pm 18.5\%$ ,  $P = 0.01$ ). There was also a significant increase in the degree of asynchrony between the thorax and abdomen (i.e. TAA) on the first postoperative day compared with preoperative values ( $43.4 \pm 55.1\%$ ,  $P = 0.01$ ). No significant pre- to postoperative change in synchronization between the operated and non-operated sides (HTA) was observed ( $163.7 \pm 230.3\%$ ,  $P = 0.08$ ).

## Effect of amount of lung removed (lobectomy versus wedge) on chest wall motion

For this analysis, patients were grouped into those who had a lobectomy ( $n = 7$ ) and those who had a wedge procedure ( $n = 8$ ). In the

lobectomy group, there was a statistically significant reduction of  $-17.1\%$  in relative contribution on the operated side on postoperative day 1 compared with preoperative values, as well as a significant increase of  $18.5\%$  on the non-operated side (both  $P = 0.03$ ) (Table 2). The degree of asynchrony between the operated and non-operated side (HTA), and between the chest wall and abdomen (TAA), was also significantly increased in the lobectomy group postoperatively ( $290.6$  and  $78.0\%$ , respectively, both  $P = 0.02$ ). Mean SLP measurements from patients who underwent wedge resection did not change significantly after surgery (Table 2). Postoperative changes in HTA and TAA were significantly higher in lobectomy versus wedge groups ( $P = 0.02$  and  $P = 0.01$ , respectively).

## DISCUSSION

In this small feasibility study performed in the acute setting of postoperative lung resection, we used SLP to examine changes in compartmental breathing patterns pre- to post-thoracic surgery. Two different components of the patients' breathing patterns were measured: relative contribution and asynchrony. Relative contribution describes the spatial displacement of each individual compartment, while asynchrony describes the temporal movement of two different compartments relative to each other. For both these components of the breathing pattern, SLP defines the dividing points as the central sternum (for division of the left and right hemi-thorax) and the xiphisternum (for division of the chest and abdomen).

In healthy individuals during quiet breathing, respiratory movements of the thorax and abdomen are generally synchronous, with phase values reported to range from  $\sim 7$  to  $23^\circ$  in those approximately the same age as the patients in our study [12]. Asynchrony between the thorax and abdomen (TAA) occurs when displacement of one side of the chest either leads or lags behind that of the abdomen. TAA has been reported to increase as a result of changes in system biomechanics such as those that occur with chronic obstructive pulmonary disease [13]. Increased TAA may have clinical implications; for example, it has been shown to predict poor performance in a 6-min walk test [14]. However, little is known about asynchrony between the right and left hemi-thorax (HTA) as it has not previously been easily measurable. It is conceivable that similar mechanisms could apply in HTA as in

**Table 1:** Baseline patient characteristics

	N = 15
Age (years)	67 (13)
Male, n (%)	10 (66.7)
Weight (kg)	79 (13)
Height (cm)	168 (13)
BMI (kg/m <sup>2</sup> )	28 (5)
Right:left side, n	11:4
Lobectomy:wedge, n	8:7
Upper:middle:lower lobe, n	10:2:2
Borg score	1 (1)
Pain score	0 (0)
FEV1 (L)	2.11 (1.11)
FEV1%	86 (27)
FVC (L)	2.23 (1.80)
FVC%	68 (52)

Data are mean (SD) except where indicated.

BMI: body mass index; FEV1: forced expiratory volume in 1 s; FEV1%: forced expiratory volume in 1 s percent of predicted; FVC: forced vital capacity; FVC%: forced vital capacity percent of predicted; SD: standard deviation.

**Table 2:** Percentage change in respiratory rate and chest wall motion from pre- to post-surgery in the lobectomy and wedge resection groups

	Lobectomy (n = 7)		Wedge (n = 8)		L versus W
	Mean (SD)	P-value	Mean (SD)	P-value	P-value
Respiratory rate	35.96 (43.37)	0.03	-1.60 (28.35)	0.67	0.03
Overall chest wall motion	15.05 (21.31)	0.13	2.09 (10.67)	0.40	0.08
Relative contribution					
Operated side of chest	-17.11 (11.34)	0.03	12.51 (20.50)	0.93	0.30
Non-operated side of chest	18.50 (12.90)	0.03	13.68 (22.97)	0.09	0.32
Asynchrony					
Operated versus non-operated side <sup>a</sup>	290.57 (222.59)	0.02	52.65 (182.91)	0.78	0.02
Chest versus abdomen <sup>b</sup>	78.01 (57.26)	0.02	13.05 (31.85)	0.26	0.01

HTA: hemi-thoracic asynchrony; L: lobectomy; SD: standard deviation; TAA: thoraco-abdominal asynchrony; W: wedge.

<sup>a</sup>HTA.

<sup>b</sup>TAA.

TAA, assuming that when an imbalance is introduced, there is sufficient mobility around the sternum.

In the present study, changes in TA motion were demonstrated. In the group as a whole, SLP detected a reduction in relative contribution on the operated side and an increase in relative contribution on the non-operated side after surgery. It is interesting to note that these changes, although occurring in opposite directions, were of a similar order of magnitude. This implies that a compensatory increase in anterior displacement of the non-operated side occurs when the opposite side is compromised due to surgery. Such a phenomenon could likely be a mechanism to preserve overall ventilation. With respect to the amount of lung removed, these postoperative changes in relative contribution were statistically significant in the lobectomy group, but did not reach significance in the wedge group. Also apparent in the lobectomy group but not in the wedge group was an increase in HTA (i. e. in asynchrony between the non-operated and operated sides), as well as an increase in TAA. These preliminary observations suggest that the magnitude of the changes in relative contribution, HTA and TAA is relative to the amount of lung removed, findings consistent with many clinicians' perspective that the amount of lung removed has an impact on post-surgery respiratory function [15]. To our knowledge, this is the first report of observed differences in displacement of, and asynchrony between, the left and right chest wall after thoracic surgery.

The findings of this feasibility study are limited by the small number of patients evaluated. Results, particularly those obtained when patients were split into subgroups based on the type of surgery, should therefore be interpreted with appropriate caution. Additional larger studies will be needed to further assess and confirm associations of changes in motion and asynchrony with specific types of surgery, and to evaluate the effect of other factors such as surgical approach (e.g. open thoracotomy versus video-assisted thoracoscopic surgery) or type of postoperative analgesia (e.g. thoracic epidural block versus paravertebral block).

In conclusion, we have described a novel methodology for the non-invasive monitoring of chest wall motion after thoracic surgery. In this small feasibility study, the SLP procedure was well accepted by patients and produced some interesting and consistent observations. Larger studies are required to corroborate and extend these findings, and in particular, to examine how these early physiological changes could predispose individuals to pulmonary complications or provide an indicator of the rate of recovery after surgery.

## Funding

This work was supported by PneumaCare Ltd (Cambridgeshire, UK) who provided half of the research doctorate fees for Ghazi Elshafie. Editorial support during development of this manuscript was provided by Aspire Scientific Ltd (Bollington, UK) and was

funded by PneumaCare Ltd. The authors had full control of the design of the study, methods used, outcome parameters, analysis of data and production of the written report.

**Conflict of interest:** Richard Iles is a shareholder of, and part-time paid medical advisor to PneumaCare Ltd. Rachel C. Wilson and Shayan Motamedi-Fakhr are employees of, and have share options for PneumaCare Ltd. No other conflicts of interest are declared.

## REFERENCES

- [1] Iyer A, Yadav S. Postoperative care and complications after thoracic surgery. In: Firstenberg M (ed.). Principles and Practice of Cardiothoracic Surgery: InTech. 2013, 57–84.
- [2] Agostini P, Cieslik H, Rathnam S, Bishay E, Kalkat MS, Rajesh PB *et al.* Postoperative pulmonary complications following thoracic surgery: are there any modifiable risk factors? *Thorax* 2010;65:815–8.
- [3] Stephan F, Boucheseiche S, Hollande J, Flahault A, Cheffi A, Bazelly B *et al.* Pulmonary complications following lung resection: a comprehensive analysis of incidence and possible risk factors. *Chest* 2000;118:1263–70.
- [4] Karlson KE, Seltzer B, Lee S, Gliedman ML. Influence of thoracotomy on pulmonary mechanics: association of increased work of breathing during anesthesia and postoperative pulmonary complications. *Ann Surg* 1965; 162:973–80.
- [5] Neely WA, Robinson WT, McMullan MH, Bobo WO, Meadows DL, Hardy JD. Postoperative respiratory insufficiency: physiological studies with therapeutic implications. *Ann Surg* 1970;171:679–85.
- [6] Nomori H, Horio H, Fuyuno G, Kobayashi R, Yashima H. Respiratory muscle strength after lung resection with special reference to age and procedures of thoracotomy. *Eur J Cardiothorac Surg* 1996;10:352–8.
- [7] Sasaki N, Meyer MJ, Eikermann M. Postoperative respiratory muscle dysfunction: pathophysiology and preventive strategies. *Anesthesiology* 2013; 118:961–78.
- [8] Siafakas NM, Mitrouska I, Bouros D, Georgopoulos D. Surgery and the respiratory muscles. *Thorax* 1999;54:458–65.
- [9] Redlinger RE Jr, Wootton A, Kelly RE, Nuss D, Goretzky M, Kuhn MA *et al.* Optoelectronic plethysmography demonstrates abrogation of regional chest wall motion dysfunction in patients with pectus excavatum after Nuss repair. *J Pediatr Surg* 2012;47:160–4.
- [10] Acosta J, Bradley A, Raja V, Aliverti A, Badiyani S, Motta A *et al.* Exercise improvement after pectus excavatum repair is not related to chest wall function. *Eur J Cardiothorac Surg* 2014;45:544–8.
- [11] de Boer W, Lasenby J, Cameron J, Wareham R, Ahmad S, Roach C *et al.* SLP: a zero-contact non-invasive method for pulmonary function testing. In: Labrosse F, Zwiggelaar R, Liu Y, Tiddeman B (eds). Proceedings of the British Machine Vision Conference. Aberystwyth: BMVA Press, 2010, 85.1–12. <http://www.bmva.org/bmvc/2010/conference/paper85/paper85.pdf>.
- [12] Parreira VF, Bueno CJ, Franca DC, Vieira DS, Pereira DR, Britto RR. Breathing pattern and thoracoabdominal motion in healthy individuals: influence of age and sex. *Rev Bras Fisioter* 2010;14:411–6.
- [13] Alves GS, Britto RR, Campos FC, Vilaca AB, Moraes KS, Parreira VF. Breathing pattern and thoracoabdominal motion during exercise in chronic obstructive pulmonary disease. *Braz J Med Biol Res* 2008;41:945–50.
- [14] Chien JY, Ruan SY, Huang YC, Yu CJ, Yang PC. Asynchronous thoracoabdominal motion contributes to decreased 6-minute walk test in patients with COPD. *Respir Care* 2013;58:320–6.
- [15] Park TY, Park YS. Long-term respiratory function recovery in patients with stage I lung cancer receiving video-assisted thoracic surgery versus thoracotomy. *J Thorac Dis* 2016;8:161–8.